

### Endovascular Reconstruction Of A Highly Calcified, Obstructed Tibial Trifurcation With Multivessel Distal Protection



Andrej Schmidt  
Clinic of Angiology  
University Hospital Leipzig, Germany

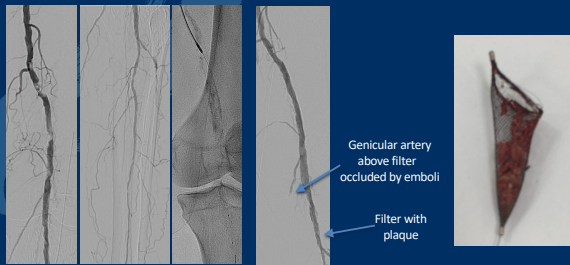
### Disclosure

Speaker name: Andrej Schmidt

I have the following potential conflicts of interest to report:  
Consulting / speaker honorarium:

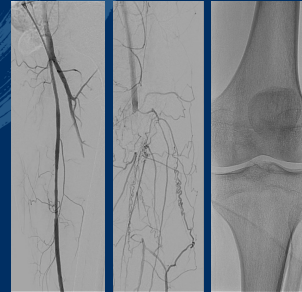
Abbott Vascular, BD, Bentley, Boston Scientific,  
ReflowMedical, Upstream Peripheral

### Risk of Embolic events during EVT / atherectomy

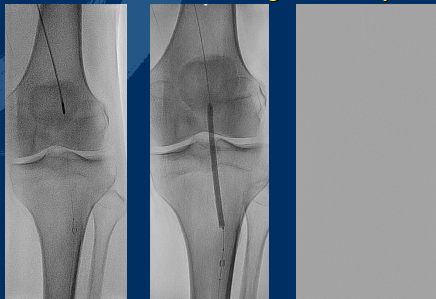

Popliteal artery atherectomy

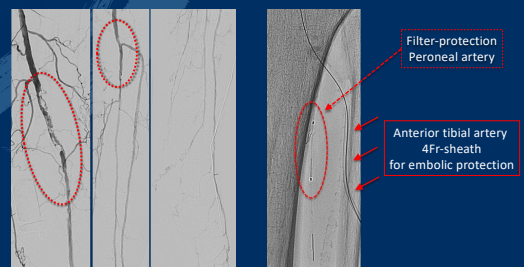
### Embolio Protection during Atherectomy



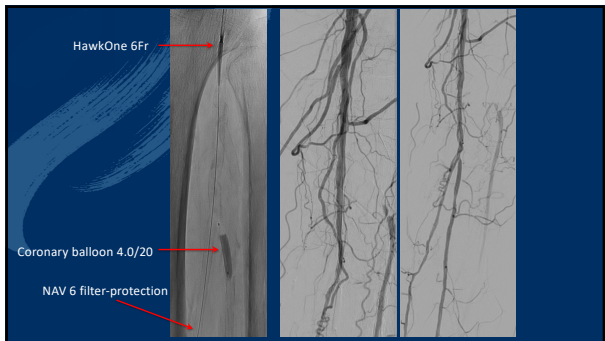
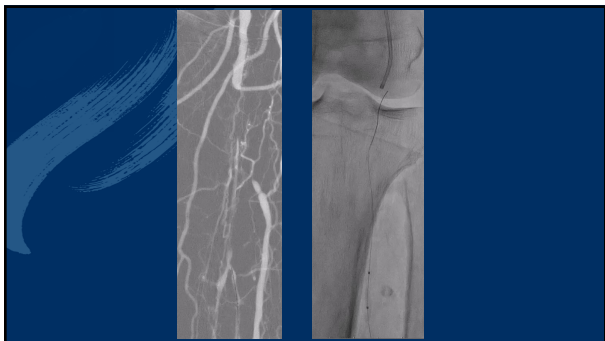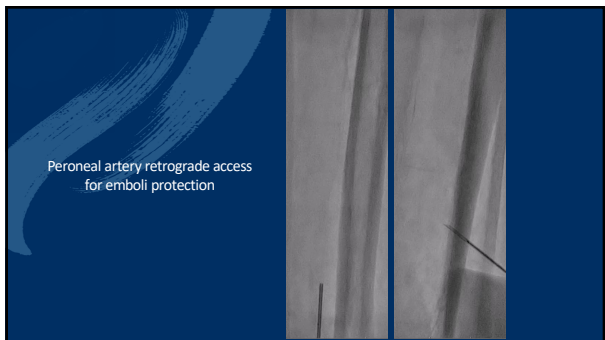
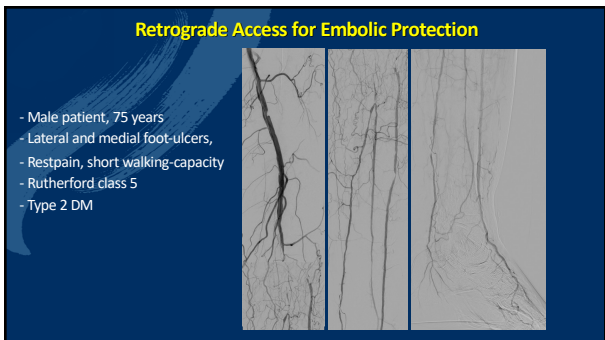
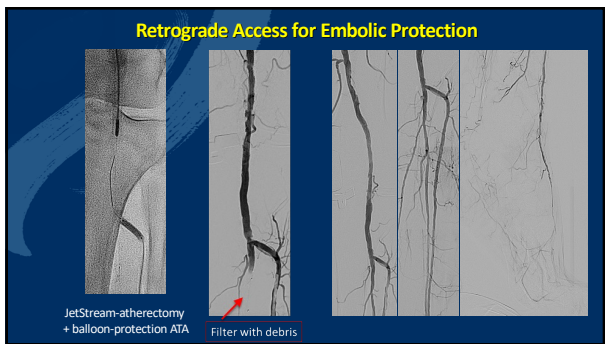
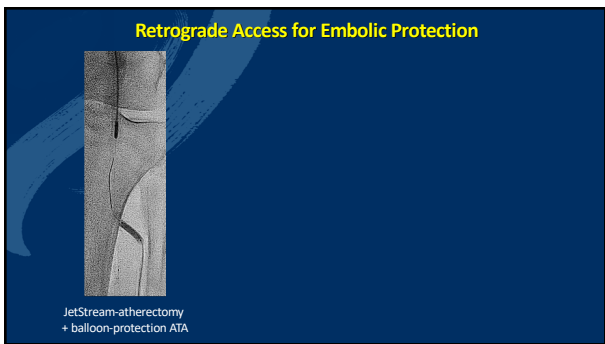
### Embolio Protection during Atherectomy

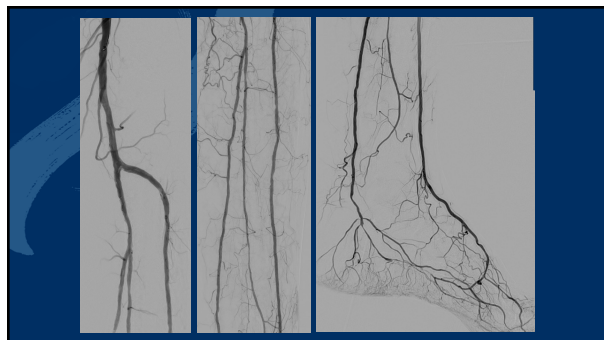
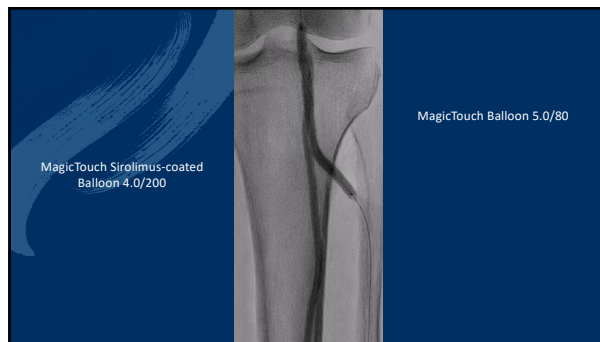
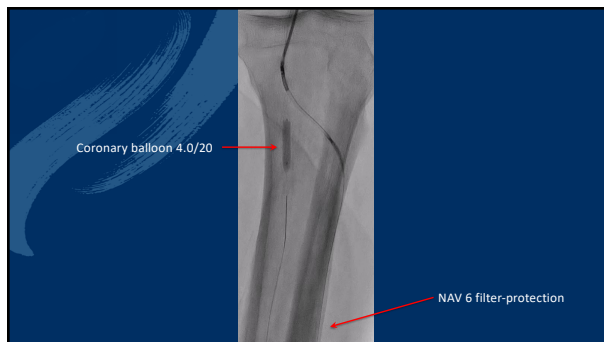


### Retrograde Access for Embolic Protection




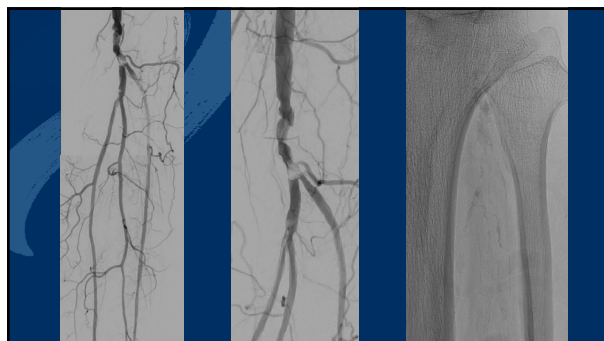
Left distal SFA / Apop atherosclerotic disease, forefoot gangrene, very poor outflow

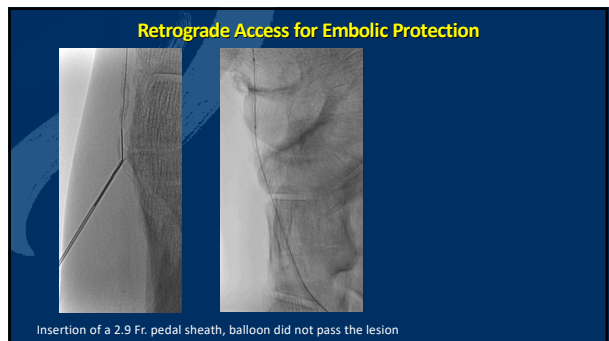
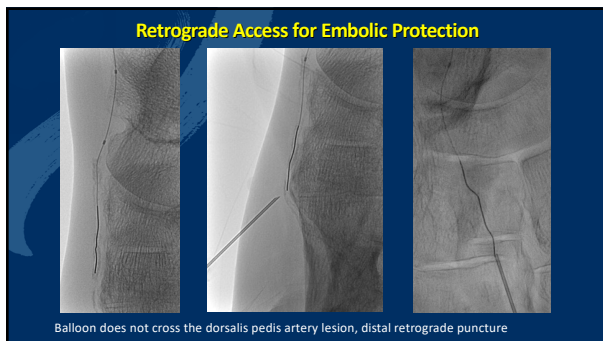
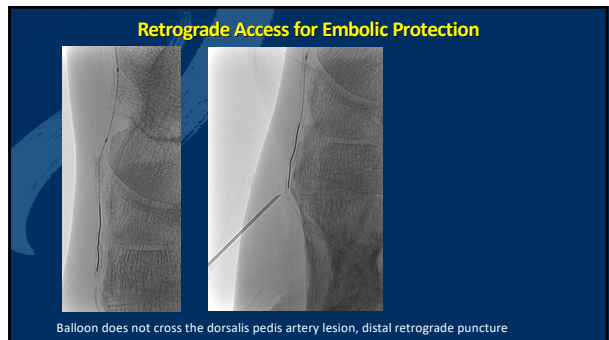
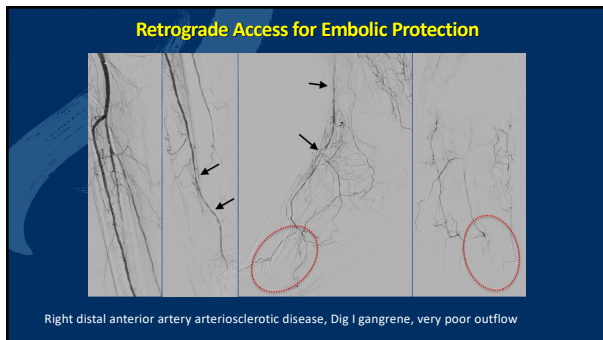
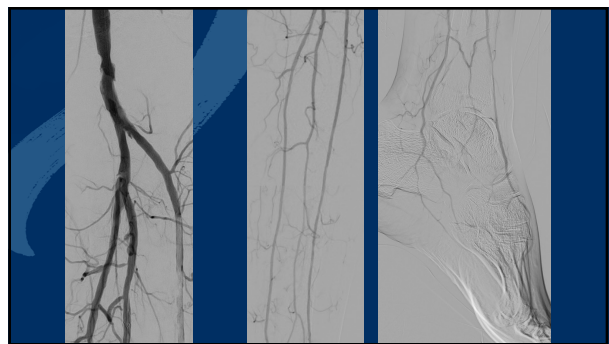
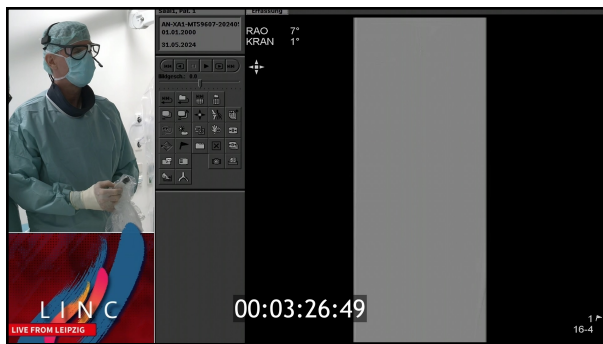


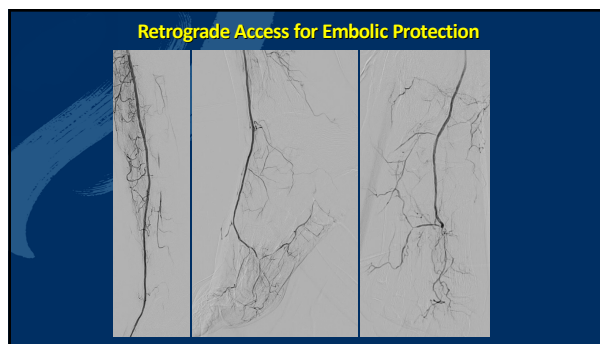
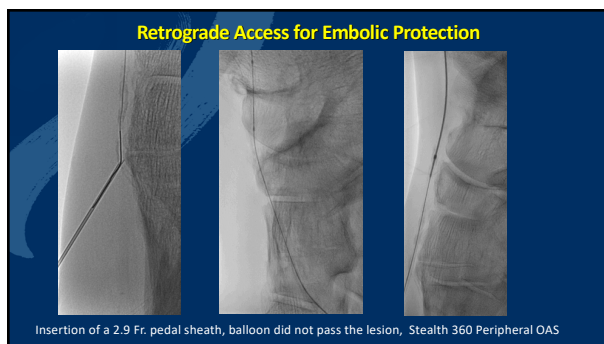


### Retrograde Access for Embolic Protection

- 72 y.o. male patient
- Restpain during, severe claudication, walking-capacity 150 meters
- ABI left 0.52
- CAD, PTCA 2021
- Type 2 DM
- Former smoker







**Conclusion**

- retrograde tibial and pedal access is safe
- embolization during atherectomy is a problem
- retrograde access for embolic-protection is a safe and effective method to avoid embolization