

**RoMed
Kliniken**

Update on the Advantages of the Chocolate Wire Constrained Uncoated Balloon Update on the Choco Cabana Trial

Prof. Dr. med. Gunnar Tepe,
Institut für Diagnostische und Interventionelle Radiologie
RoMed Klinikum Rosenheim

VEITH
INSTRUMENTAL
Catalyzing the Percutaneous Community

Disclosure

Study support by B.Braun, Biotronic, BSC, CVT, Philips, Medtronic, Shockwave

VEITH
INSTRUMENTAL
Catalyzing the Percutaneous Community

BTK Arteries: Different vessels

Above the Knee¹

- Multiple plaque types (mixed morphology)
- Large plaque burden²
- Medium to large vessels (4-9 mm)

Below the Knee¹

- Lesions more commonly calcified
- Dense calcium comprises a greater percentage of plaque (27% in tibial vs 12% in popliteal arteries)
- Small vessels (2-3.5 mm)
- Tortuous anatomy

1. Vasa 2011 survey - 100 prevalence survey
2. Research of Arter. Soc. Sup. 2008;22:799-805

VEITH
INSTRUMENTAL
Catalyzing the Percutaneous Community

BTK Arteries: What is the problem?

Limitations because of
1. Calcification 2. Recoil 3. Dissections 4. Restenosis

PTA

A: How much is caused by recoil and how much is caused by restenosis?
B: Is it possible to reduce recoil?

VEITH
INSTRUMENTAL
Catalyzing the Percutaneous Community

BTK Arteries: Different vessels

Most BTK vessels undergo significant elastic recoil following angioplasty¹

Medial calcification produces vessel recoil and restenosis^{2,3,4}

```

    Medial calcification → Arterial Stiffness → Vessel recoil → Restenosis
    
```

1. Bourcier et al. Early recoil after balloon angioplasty of iliofemoral obstructions in patients with critical limb ischemia. JInterven Ther 2014
2. Gombert et al. Restenosis after balloon dilatation of iliofemoral artery stenosis. JInterven Ther 2008
3. Gombert et al. Restenosis of iliofemoral obstructions after PDBA. JInterven Ther 2008
4. Gombert et al. Restenosis of iliofemoral obstructions after PDBA. JInterven Ther 2008

VEITH
INSTRUMENTAL
Catalyzing the Percutaneous Community

The Chocolate PTA Balloon

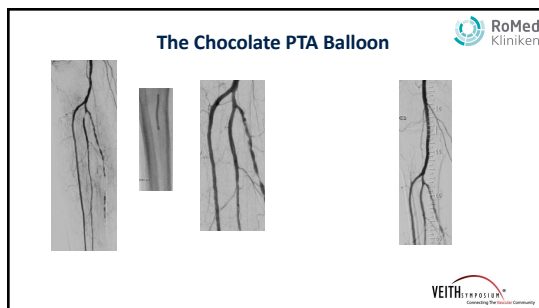
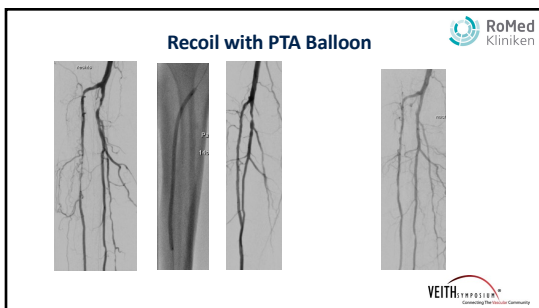
Chocolate Bar Study^{1,2}: Overview

Chocolate Bar Study^{1,2}: Outcomes

Lesion characteristics	N = 263
Lesion length (mm)	83.5 ± 59.9 (n = 250)
Total occlusions	60/260 (23.1%)
Lesion calcification	
Severe	93/254 (36.6%)
Moderate	110/254 (43.3%)
None	51/254 (20.1%)

Prevalence Success	95% CI	95% CI
Freedom from Flow Limiting Obstruction* (All Reporters)	87.7%	86%
Freedom from Flow Limiting Obstruction* (Major Reporters)	100%	100%
Adherence >90% (Device Success) (Major Reporters)	84.1%	84.4%
Freedom from Major Out-Of-Stenting	84.4%	84.1%
Freedom from Target Lesion Revascularization	87.7%	87.7%
Freedom from Major Unplanned Angioplasty	87.2%	86.7%
Freedom from All-Cause Revascularization	83.3%	82.7%

VEITH
INSTRUMENTAL
Catalyzing the Percutaneous Community



Choco Cabana Study

RoMed Kliniken

Chocolate PTA Balloon compared to conventional balloon angioplasty for sustained lumen gain in below the knee arteries

- Prospective
- Randomized
- Single blinded
- Multiple Centre
- International

VEITH INFOSISIA

Choco Cabana Study

RoMed Kliniken

Aims

1. Assess the degree of vessel recoil (angiography after 15 min – comparison with inflated balloon and initial result)
2. Assess if and in what the degree the Chocolate PTA balloon reduces vessel recoil (60 vs. 60 patients)
3. Assess if the vessel recoil has an effect on the degree of stenosis at 6 months (MRA or DSA at 6 months)
4. Assess the clinical relevance of vessel recoil

VEITH INFOSISIA

Choco Cabana Study

RoMed Kliniken

Main inclusion criteria


1. RF 2-5
2. LL: 1-25cm
3. All lesions should be treated either by POBA or Chocolate PTA (longest lesion = study lesion)
4. Sufficient outflow distal of the lesion
5. Inflow treatment up to TASC B
6. No vessel prep allowed (Cutting balloon, atherectomy, lithoplasty,...)
7. No post-dilatation with a DCB

VEITH INFOSISIA

Choco Cabana Study

RoMed Kliniken

Study centres



- 01 Rosenheim, RoMed Klinikum Rosenheim, Prof. Dr. med. Gunnar Tepe
- 02 Bad Krozingen, Herzzentrum Bad Krozingen, Prof. Dr. Thomas Zeller
- 03 Tübingen, Universitätsklinikum Tübingen, Diagnostische und interventionelle Radiologie, PD Dr. Gerd Grözinger
- 04 Karlsbad-Langensteinbach, SRH Klinikum Karlsbad-Langensteinbach GmbH, Interdisziplinäres Gefäßzentrum, Prof. Dr. Erwin Blessing
- 05 Radebeul, Elblandklinikum Radebeul, Interdisziplinäres Gefäßzentrum, Dr. Torsten Fuß
- 06 Graz, LKH-Univ. Klinikum Graz, Univ. Klinik für Innere Medizin, Klin. Abteilung für Angiologie, Prof. Dr. med. Marianne Brodmann
- 07 Wien, Hanusch-Krankenhaus, Kardiovaskuläres Zentrum, Angiologische Ambulanz, Dr. Martin Werner

VEITH INFOSISIA