

How Can Type I Endoleaks Cause Sac Pressurization (Endotension) Without Contrast Visualization: How To Detect And Treat It: What Else Can Cause Endotension

Kenneth Ouriel, MD, MBA
Chief Medical Officer and CRO Business Unit Leader
NAMSA

VEITH Symposium
November 20, 2024
New York, NY

Ouriel Disclosures

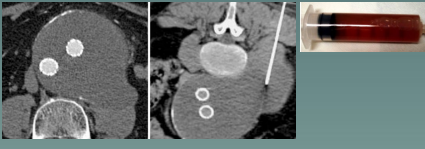
Disclosures

KO is an employee of NAMSA, a Clinical Research Organization that receives funding from medical device companies to perform clinical trials, some of which is related to the study of endovascular treatment of aortic aneurysms.

Type I Endoleaks Without Contrast Enhancement 2024 VEITH Symposium

Endotension (Type V Endoleak): Sac Enlargement Without a Discernable Endoleak

Why doesn't intra-sac thrombus resolve?



Rand T. Ubieri R, CI R, Munnecke G, Tsetsis D. Quality improvement guidelines for imaging detection and treatment of endoleaks following endovascular aneurysm repair. Cardiovasc Intervent Radiol (2012).

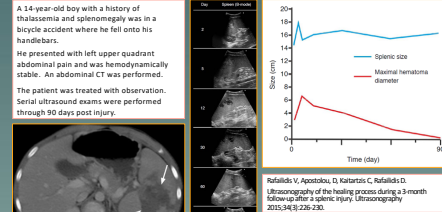
Type I Endoleaks Without Contrast Enhancement 2024 VEITH Symposium

Resolution of Blood Collections in the Body

Why do some hematomas resolve and yet thrombus outside of an endograft often remaining over long periods of time after aneurysm repair?

Suggestion: There is at least pressurization if not flow in the sac when the intraluminal thrombus does not resolve over time.

A 14-year-old boy with a history of thalassemia and splenomegaly was in a bicycle accident where he fell onto his handlebars. He presented with left upper quadrant abdominal pain and was hemodynamically stable. An abdominal CT was performed. The patient was treated with observation. Serial ultrasound exams were performed through 90 days post injury.



Rafailidis V, Apostolou, D, Karantis C, Rafailidis D. Ultrasonography of the healing process during a 3-month follow-up after a splenic injury. Ultrasonography 2015;34(3):236-240.

Credit to Dr David Deaton for his hypothesis after observation of patients post Nellis AAA repair.

Type I Endoleaks Without Contrast Enhancement 2024 VEITH Symposium

Potential Causes of Endotension

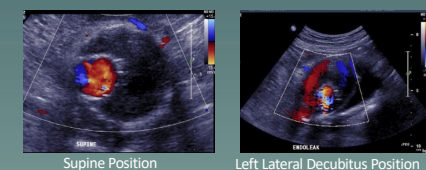
Why would sac enlargement occur without a demonstrable leak of contrast into the sac?

Four Mechanisms (there are more...)

1. Sac enlargement occurs due to an intermittent leak, usually positional, not seen on a CT scan.
2. Small leaks undetected on a standard CT scan transmit pressure to the sac.
3. Transudation of fluid through graft interstices causes fluid accumulation and increases in intra-sac pressure.
4. Inadequate seal proximally or distally is associated with transmission of pressure through the thrombus, without contrast entering the sac.

Type I Endoleaks Without Contrast Enhancement 2024 VEITH Symposium

1. Intermittent, Posture-Dependent Endoleaks "Positional Endoleaks"



Supine Position
No Endoleak Visualized

Left Lateral Decubitus Position
Obvious Endoleak

May J and Harris J. Semin Vasc Surg. 2012, 25:167-73

Type I Endoleaks Without Contrast Enhancement 2024 VEITH Symposium

2. Tiny fabric defects too small to be seen on CT "Microleaks"

Matsumura JS, Ryu RK, Curiel K. J Vasc Surg 2001; 34:190-97

Type I Endoleaks Without Contrast Enhancement 2004 VEST Symposium

3. Transudation through endograft interstices

Initial Gore Excluder graft, rapidly addressed and corrected

King et al. J Vasc Surg 2020

Type I Endoleaks Without Contrast Enhancement 2004 VEST Symposium

4. Transmission of Pressure Through Thrombus

A common cause of endotension observed today

Classification of Type I endoleaks: Argues for classification of failed apposition within the attachment zone as a Type I endoleak.

Endoleak Types in Nellix Study:

1. Contrast in neck, between endograft and wall, but not entering sac.
2. Contrast between endobag and wall of sac.
3. Contrast between the two endobags within the sac.
4. Evidence of aneurysm sac pressurization.

Newer Classification of Type I Endoleaks:

1. No contrast within the sac but absent apposition of the endograft within the attachment zone.
2. Contrast between the endograft and the neck of the aneurysm at the attachment zone, but no contrast in the sac.
3. Contrast within the aneurysm sac.

Occurrence and Classification of Proximal Type I Endoleaks After Endovascular Aneurysm Grafting Using the Nellix Device, van den Ham a LH, Gibberik R, Sankhwar S J, Wittecoaten A, Curiel K, Rajaram M. Eur J Vasc Endovasc Surg 2017; 54: 729-736.

Type I Endoleaks Without Contrast Enhancement 2004 VEST Symposium

Does Aortic Thrombus Transmit Pressure?

Effect of intraluminal thrombus on pressure transmission in the abdominal aortic aneurysm, Hirani M, Koning CH, Vener MP, van Bockel HJ. Vasc Surg 2005; 42:1176-82

Yes, with a small decrement as the distance from the lumen increases 90% at 1cm, 86% at 2cm and 80% at 3cm.

Type I Endoleaks Without Contrast Enhancement 2004 VEST Symposium

No "Endoleak," but Enlargement and Rupture

Historical experience...

Wired aneurysm: Post-mortem angiogram

Wired AAA, circa 1950s
Enlargement, Rupture
But no contrast extravasation

University of Rochester Medical Center
Strong Memorial Hospital

Type I Endoleaks Without Contrast Enhancement 2004 VEST Symposium