

**Update On The Experience With BeGrafts (From Bentley),
A Balloon Expandable Covered Stent For Treating Aortic
Coarctations, Aneurysms And Midaortic Syndrome:
Advantages And Limitations**

E. Bruckheimer, MBBS.

Director, Cardiac Catheterization, Section of Pediatric Cardiology,
Schneider Children's Medical Center - Israel, Petach Tikva, Israel.

Disclosures

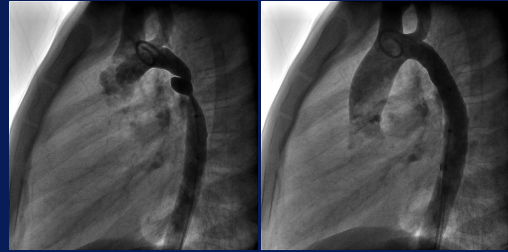
Consultant and Proctor for Bentley Innomed

Aortic BeGraft

- Bentley ePTFE covered outside – cobalt chromium open cell
- W 12, 14 - 20, 16, 18 - 24mm, 20, 22, 24 - 30mm L 29-59mm
- premounted on Bentley MP balloon
- Sheath size 9-14Fr
- Can be further dilated with balloons
- Minimal recoil

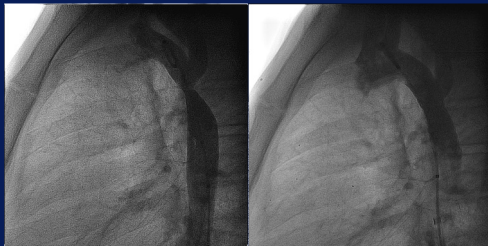

Coarctation of Aorta – BeGraft



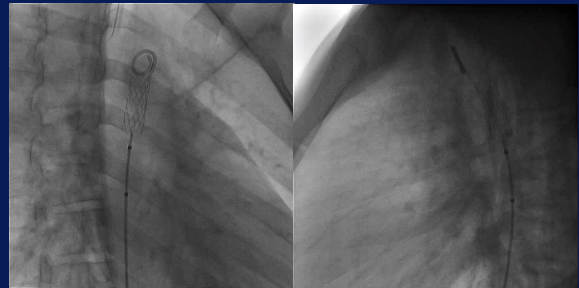
9 year old native coarctation 12mm 39mm Bentley no post dilatation

Coarctation of Aorta – BeGraft

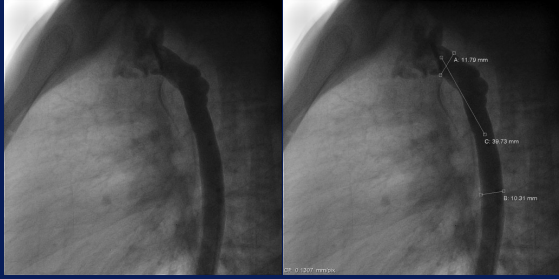


17 year old native coarctation - implanted 12mm-39mm to cover 2/3 of the orifice of the left subclavian artery post dilated with a 14mm and the 16mm Atlas balloon

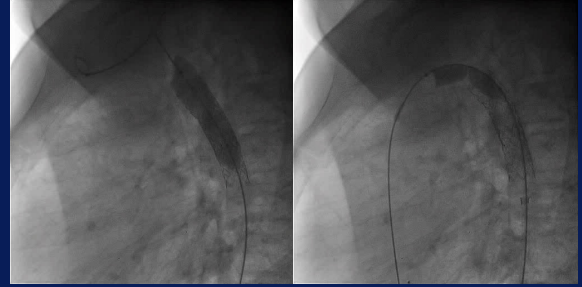
CoA – Bare stent - Aneurysm



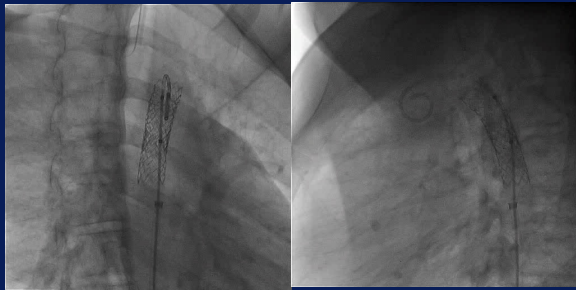
CoA - Aortic BeGraft



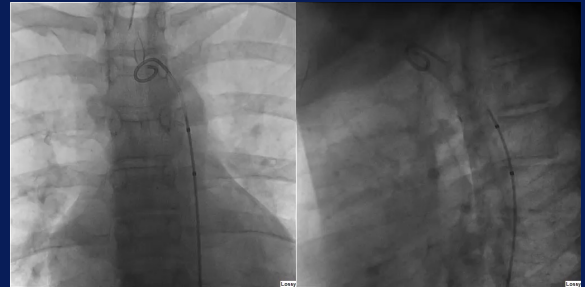
CoA - Aortic BeGraft – Maxi LD shaping



CoA - Aortic BeGraft

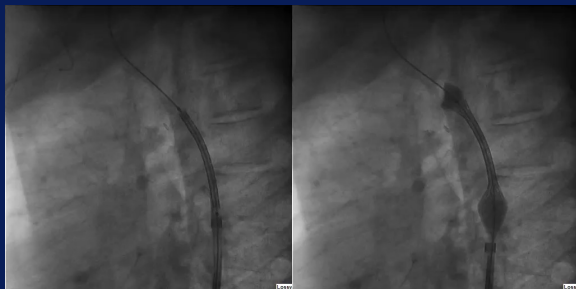

Coarctation of Aorta – BeGraft



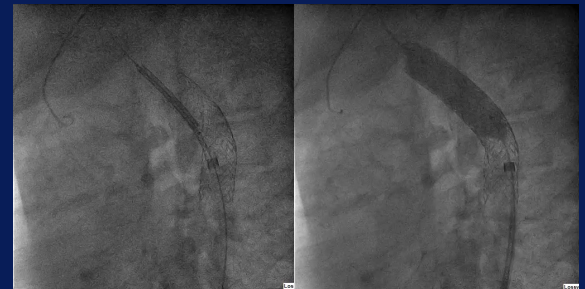
17 year old s/p surgery coarctation mild + aneurysm - telescoped 3 1648 Aortic BeGrafts - distal to proximal

Coarctation of Aorta – BeGraft



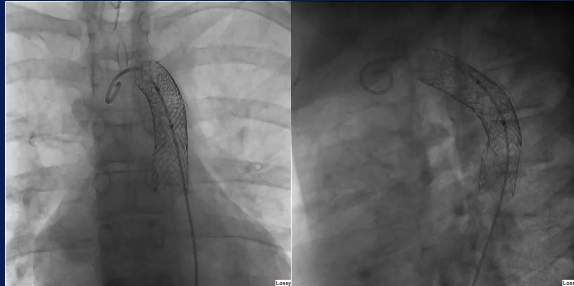
17 year old s/p surgery coarctation mild + aneurysm - telescoped 3 1648 Aortic BeGrafts - distal to proximal

Coarctation of Aorta – BeGraft



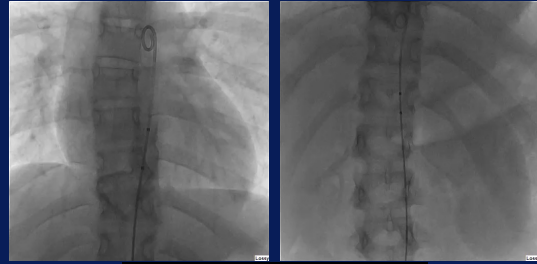
17 year old s/p surgery coarctation mild + aneurysm - telescoped 3 1648 Aortic BeGrafts - distal to proximal

Coarctation of Aorta – BeGraft



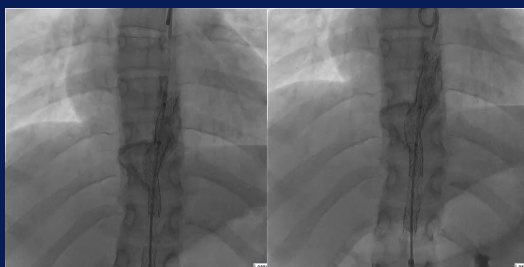17 year old s/p surgery coarctation mild + aneurysm – telescoped 3 1648
Aortic BeGrafts – distal to proximal – post dilated MaxiLD 18mm

CoA aneurysm in smaller aortas/children



9 year old mid aortic s/p endovascularitis

CoA aneurysm in smaller aortas/children



9 year old mid aortic s/p endovascularitis

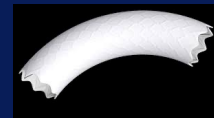Bentley BeGraft for CoA

- 2/2017- 8/2024
- 78 pts [54M, 24F] - median age 14.1yrs [2.7-52.8]
- weight 48.1kgs [12.5-108.1]
- CoA - 36 native
- 54 pre Tx - 27 s/p stent (19B 8C), 27 s/p surgery
- 8 aneurysms - 2 s/p Tx Covered CP stent
- BeGraft Aortic [12 (56), 14 (7) or 16(5)] via a 9-11Fr, femoral artery, implanted and post dilated through the same delivery sheath.
- Systolic peak gradient decreased from 20.1 ± 8.8 to 4.2 ± 4.3 mmHg [$p=0.001$]
- CoA diameter increased from 7.5 ± 3.5 to 13.1 ± 2.2 mm [$p=0.0001$] [Tadia 13.0 ± 2.4]
- CoA final diameter : final balloon diameter 0.93 ± 0.05

Bentley BeGraft for CoA

- There was no acute aortic wall injury nor other immediate complications.
- 8 patients underwent successful occlusion of the pre-existing aneurysms.
- Follow up 3.6 yrs [0.2 – 7.4]
 - 34 pts imaged [10 CT, 2 MRA, 22 cath] - 2 new aneurysms
 - 22/73 patients [30%] underwent cath at a median of 3.4 yrs [0.5-5.2] after initial BeGraft
 - stent diameter cath 1 : stent diameter cath 2 1.0 ± 0.05
 - 12 patients balloon redilation, 6 somatic, 6 restenosis
 - 5 patients further stent implantation, 3 restenosis, 2 new aneurysm [1 endovascularitis]
 - 5 patients did not require any intervention

Aortic BeGraft



- Very robust stent
- Excellent covering
- Low profile – easy to use - delivery system
- Easily further dilated with high pressure balloons
- Minimal recoil
- Long term F/U imaging is essential to assess long term performance