


### Short and Long-term Results for Endovascular Therapy for Infected Aortic Aneurysm at Various Levels

An 18-year, 175-case Experience:


**EVAR Can Work**

Boonprasit Kritpracha, MD, Wittawat Tantarattanapong, MD  
 Pong Juntarapatin, MD, Sorrascha Rookapan, MD  
 Supong Warathanmanon, MD, Pitikom Brianakkawanich, MD



### Disclosure

- None



### Endovascular Therapy for Infected Aortic Aneurysm

Several reports/reviews, past 10+ years


Endovascular therapy for infected aortic

**Good short-term & mid-term results**

**Long-term results**  
**Recurrent rates**

Myerle Aneurysm Aortic Repair with Endovascular Stents  
 The feasibility of a strategy in treating  
 Early and Late Open Aneurysm Repair for Aortic and/or Iliac A

Systematic Review  
 Karl Strömke, Jacob Buehler  
 Department of Hospital Services, etc.




### Endovascular Therapy for Infected Aortic Aneurysm

September 2005 – May 2024

175 cases: 142 males, 33 females  
 Average age 64.8 years (39-90)

Thoracic 31  
 Visceral-branch segment 26  
 Abdominal 113

Multiple levels 5



### Infected Aortic Aneurysm

PSU's rationale

Fever, abdominal/chest pain, ↑ WBC, ESR, CRP, ⊕ blood culture, Characteristic findings on CT study

No Antibiotics

T/EVAR

Leakage – Emergency  
 No leakage – Urgency

Pain: Immediately improved  
 Fever: subsided within 3-5 days

Re-evaluation


Persisted fever / pain  
 - ↑ antibiotics regimen  
 - ↑ intraoperative collection

Need for conversion

Oral Antibiotics  
 Lifelong

Organisms

Salmonella	26%
MSSA	21%
Streptococcal spp.	17%
Burkholderia pseudomallei	10%
E. Coli	8%
TS	5%
Klebsiella spp.	3%
Corynebacterium Stratum	2%
Pseudomonas spp.	2%



### Endovascular Therapy for Infected Aortic Aneurysm

Total 175 cases

Non-fistula group 150 (86%)


Fistula group 25 (14%)

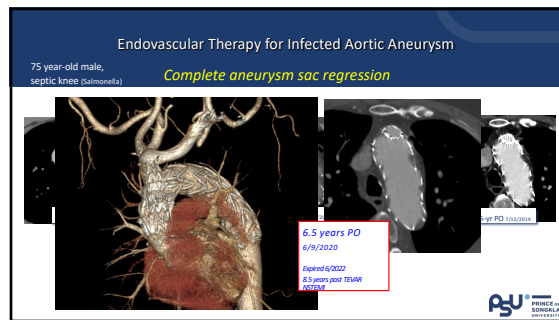
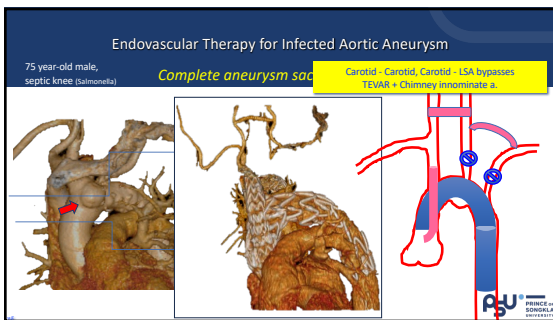
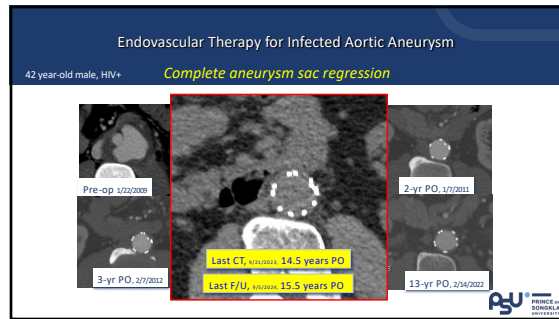
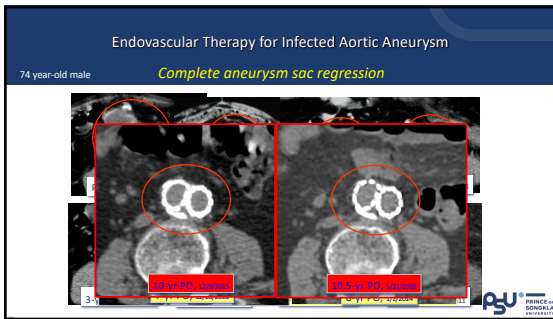
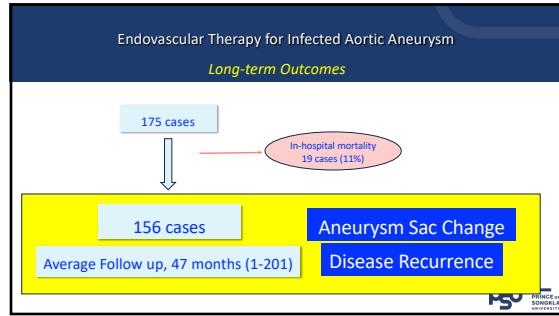
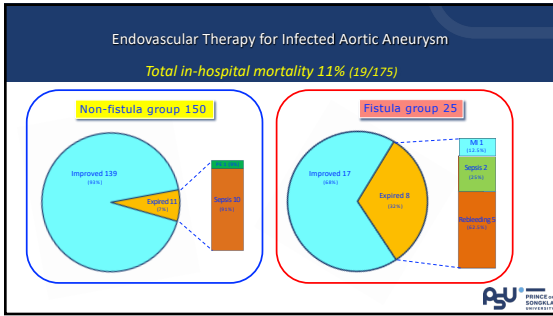
Microbial aortitis

In hospital MR 7% (11/150)

overall mortality 11% (19/175)

In hospital MR 32% (8/25)





### Endovascular Therapy for Infected Aortic Aneurysm

45 year-old female **Multi-level aortic infection**

Pre-op, 11/24/2011

Last CT, 9.5 years PO

Last F/U, 12+ years PO

9.5-yr PO, 11/10/2014

4.5-yr PO, 1/10/2014

PSU PRINCETON UNIVERSITY

### Endovascular Therapy for Infected Aortic Aneurysm

55 year-old male **Visceral-branch level aortic infection**

Pre-op

3.5 years PO

8.5 years PO

PSU PRINCETON UNIVERSITY

### Endovascular Therapy for Infected Aortic Aneurysm

68 year-old male **Multi-level aortic infection**

TEVAR + LSA stent-graft (P44143)  
E inside multi-branch stent-graft

Pre-op

TAA 65 mm

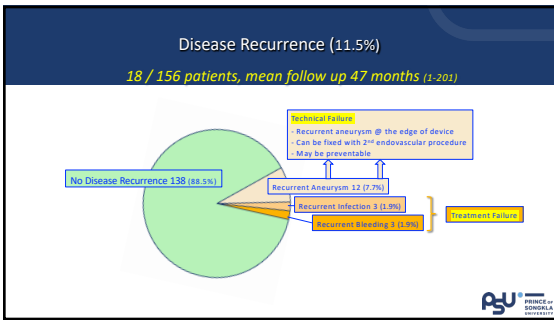
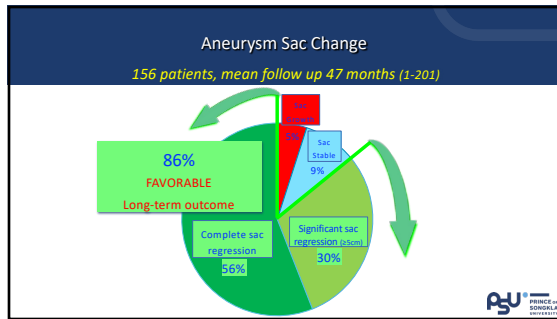
AAA 80 mm

1-year PO

TAA 55 mm

AAA 40 mm

PSU PRINCETON UNIVERSITY



### Endovascular Therapy for Infected Aortic Aneurysm

52 year-old male **Recurrent disease @ the "proximal edge" of the stent graft**

Procedure-related failure  
Inadequate Proximal Coverage

Pre-op

Juxtarenal infected AA

2-renal chimney EVAR

1.5-year PO

2.5-year PO

PSU PRINCETON UNIVERSITY

**Endovascular Therapy for Infected Aortic Aneurysm**  
*Recurrent disease @ the "proximal edge" of the stent graft*

Proximal Cuff Extension  
 Chimney SMA  
 Extended 2 Renal Chimneys EVAR

Total aneurysm shrinkage

6.5 years post (1<sup>st</sup>) OP  
 4 years post (2<sup>nd</sup>) OP

PSU PRINCE OF GEORGIA UNIVERSITY

**Endovascular Therapy for Infected Aortic Aneurysm**  
*Recurrent disease @ the "distal edge" of the stent graft*

61 year-old male

Procedure-related failure  
 Inadequate Distal Coverage

Distal extension  
 3-branch, CMD

6 years post 1<sup>st</sup> OP  
 3 years post 2<sup>nd</sup> OP

Pre-op 3-yr PO

PSU PRINCE OF GEORGIA UNIVERSITY

**Endovascular Therapy for Infected Aortic Aneurysm**  
*Recurrent bleeding*

77 year-old male

Procedure-related failure  
 Inadequate Proximal Coverage

Aorto-enteric fistula  
 2 Aortic cuffs insertion, 10/12/2006

1 cm

Re-bleeding  
 1-mo PO, 11/12/2006

Re-intervention, AUI  
 1-mo PO, 11/12/2006

PSU PRINCE OF GEORGIA UNIVERSITY

**Endovascular Therapy for Infected Aortic Aneurysm**  
*Recurrent infection*

68 year-old female

Procedure-related failure  
 Lost to F/U, for 3 years

Explant

OR, 8/15/12

5-yr PO, 4/28/2017

8-yr PO, 3/16/2021

PSU PRINCE OF GEORGIA UNIVERSITY

**CONCLUSIONS**

- Endovascular therapy + Long-term (life-long) antibiotics is an effective treatment for patients with infected aortic aneurysm, both --
  - **Short-term:** particularly in "non-fistula" cases (in-hospital MR 7%)
  - **Long-term:** average f/u 47 months (1-201), 156 cases
    - Good clinical outcomes (88.5%)
    - Good imaging study outcomes (total aneurysm collapse / significant shrinkage) (86%)
- 2 types of failure (11.5%):
  - Procedure-related (Technical) -- majority (7.7%), preventable
  - Infection-related -- serious but not common (1.9% each)
- Adequate coverage both proximal and distal aorta is important.

PSU PRINCE OF GEORGIA UNIVERSITY

**Thank you**

PSU PRINCE OF GEORGIA UNIVERSITY